

# Adenocarcinoma of fallopian tube with tubercular salpingitis

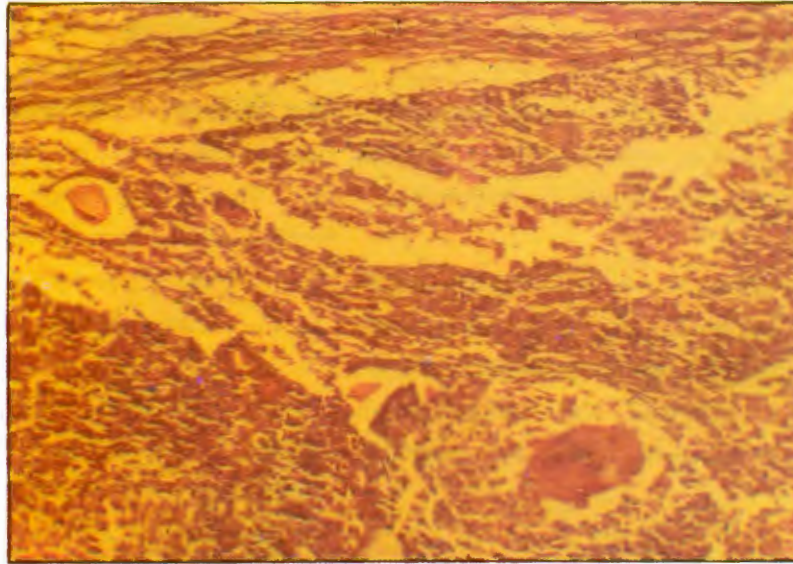
Krishna Khushlani • Rajrani Sharma • Nazima Saloda,  
Dept. of Obstet. & Gynaecol., R.N.T. Medical College, Udaipur (Raj.)

Manna Bai W/o Ganesh Ram 19 years of age, resident of Nimach (M.P.) reported to Zanana Hospital, Udaipur with complaint of infertility on 22.2.97. On examination patient was pale and moderately built and nourished. Per vaginal examination revealed uterus anteverted anteflexed with a cystic ovarian mass in left fornix about the size of an orange. Ultrasonography

revealed thickened endometrium with ascites and left ovarian cyst approximately 65 mm in size. On exploratory laparotomy 400 c.c. of clear and colourless peritoneal fluid was drained. There were granulomatous lesions on omentum which appeared to be tubercular. Left sided ovariectomy done. During the procedure the cyst

ruptured and brown color liquid was extruded. Opposite

tube was thickened and cord like and there were fimbrial adhesions. H P R obtained 6 days later surprisingly showed nodular structures with features of fallopian



Adenocarcinoma of Fallopian-tube with tubercular Salpingitis  
\* features of well differentiated adenocarcinoma  
\* Giant cell indicative of Tuberculosis

tube with tubercular salpingitis, ovary showed normal histology with luteal cyst. Adenocarcinoma of fallopian tube is a very rare malignancy, its incidence being only 0.5% and it is still rare to find in a young teenager. Its association with tubercular infection was an interesting feature in this case.